



CASE REPORT

Nocardia Nova Causing Chronic Maxillary Sinusitis: A Rare Case

Kiran Chawla, Frenil C Munim, Sugandhi P Rao, Suresh Pillai*

Abstract

Nocardia as an etiological agent for sinusitis has rarely been reported. Only three such cases have been reported so far in literature. We report here, a first case from India, of chronic maxillary sinusitis caused by Nocardia nova in an immunocompetent male and patient responded well to treatment by co-trimoxazole

Key Words

Nocardia Nova, Sinusitis, Immunocompetent

Introduction

Nocardiosis is considered to be an opportunistic infection and it most commonly presents as pulmonary disease in immunocompromised persons. Nocardia as an etiological agent for sinusitis has rarely been reported. Only three such cases have been reported so far in literature (1,2,3). Herein, we are reporting a first such case from India, of chronic maxillary sinusitis caused by Nocardia nova in an immunocompetent male, as well as a review of previously reported cases.

Case Report

A 43-year-old male presented at the outpatient otorhinolaryngology department with chief complaints of nose block and a watery, non-foul smelling nasal discharge since one and half months. The nose block described by him was bilateral, intermittent, insidious in onset and gradually progressive in nature. The patient gave the history of snoring and mouth breathing since ten years. His medical past history was insignificant except for getting diagnosed as a diabetic one and half year ago and was on oral hypoglycaemic agent. On admission, the patient's vitals were stable. Examination of nose revealed gross deviated nasal septum with spur on the left side and bilateral hypertrophied inferior turbinate. Cold spatula test showed decreased fogging on the left side. There was absence of tenderness on paranasal sinuses. Examination of ear, oropharynx and neck were within normal limit. Laboratory investigations revealed haemoglobin of 16.5 gm dl-1, a total leukocyte count of

6,900 cells mm-3 with 50.6% neutrophils, 29.4% lymphocytes, 8.9% monocytes, 10% eosinophils and 1.1% basophils and a platelet count of 2,26,000 cells mm-3. Absolute neutrophil count was $3.5 \times 10^3/\mu\text{l}$ and absolute eosinophil count was $0.7 \times 10^3/\mu\text{l}$. LFT (liver function tests), RFT (renal function tests) and serum electrolytes were normal. Serology for human immunodeficiency virus and hepatitis B virus was negative. Fasting blood sugar level was 171 mg dl-1 and post-prandial blood sugar level was 222 mg dl-1 for which he was referred to the internal medicine department to achieve glycaemic control. His chest X-ray findings were within normal limit. HRCT of paranasal sinuses revealed pansinusitis with left DNS with bony septal spur. (Fig 1) He was started on tablet cefpodoxime-clavulanic acid 200mg BD and other symptomatic treatment. Once euglycemia was achieved, septoplasty and functional endoscopic sinus surgery with left spur removal was performed. Mucoid discharge collected intra-operatively from the left maxillary sinus was sent for aerobic, anaerobic and fungal culture. Blood agar and Sabouraud's Dextrose agar showed small, dry colonies after 3 days of incubation. Gram staining of the growth revealed Gram positive filamentous bacilli. Colonies were identified as Nocardia nova complex with the standard tests that included colony and microscopic morphology, susceptibility to lysozyme, and failure to hydrolyze casein, xanthine, tyrosine, or hypoxanthine. (Fig 2) Antimicrobial susceptibility testing was performed

From the Department of Microbiology and *ENT, Kasturba Medical College, Manipal, Karnataka, India

Correspondence to : Dr Kiran Chawla, Associate Professor, Department of Microbiology, Kasturba Medical College, Manipal, 576104 Karnataka, India

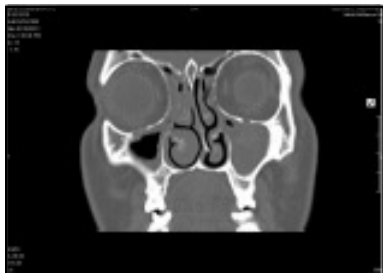

Fig 1. Coronal Section of Osteomeatal Complex Showing Mucosal Thickening of all the Sinuses, Deviation of Nasal Septum to the Left with Bony Septal Spur Impinging on the Inferior Turbinate and Atrophy of Left Turbinate along with Compensatory Hypertrophy of Right Turbinate

by disc diffusion test according to Clinical Laboratory Standard Institute which showed sensitivity to amikacin, trimethoprim-sulfamethoxazole, ceftriaxone and gentamicin, but resistance to amoxicillin-clavulanic acid, ampicillin, ciprofloxacin, erythromycin and doxycycline. Patient was started on trimethoprim-sulfamethoxazole (TMP-SMX) for 6 weeks and improved gradually over the period of time.

Discussion

Nocardia species are environmental saprophytes, living in soil, organic matter and water. They are infrequently recognized to cause clinical disease in normal patients, but they are more frequently diagnosed as causing disease in immunocompromised patients (4). The predisposing factors are long-term corticosteroid therapy, diabetes mellitus (DM), chronic lung disease, hematologic and other malignancies and organ transplantation, mainly in renal transplant patients (5). *Nocardia* can cause pulmonary or disseminated infections or, more rarely, subcutaneous actinomycotic mycetomas by direct skin inoculation (6).

Nocardia as an etiological agent for sinusitis has rarely been reported. Except for the presence of DM, there was no other predisposing immunocompromising factor in our patient. Inhalation is the most probable mode of infection in the present case and presence of protracted nose block reinforced by presence of DM may have contributed to sinusitis by *Nocardia*. We reviewed the literature and found out that only three such cases have been reported so far (1,2,3). All the three described patients were immunocompetent.

The species identification of *Nocardia* can be done biochemically and by molecular techniques. The availability of newer molecular methods such as 16S ribosomal RNA sequencing, hsp65 PCR and 16S restriction enzyme analysis (PRA) appears to be an




Fig 2. Growth of *Nocardia nova* on Nutrient Agar

improvement and recognizes >90% of currently recognized clinical species (7). But molecular detection needs a good set up and high expertise. We could not perform the molecular work-up because of resource constraints.

TMP-SMX is the treatment of choice for *Nocardia* infections. All the earlier described cases of sinusitis caused by *Nocardia* responded well to TMP-SMX except in a case reported by Unzaga MJ et al (3) where patient could not tolerate it and was given a 6-week course of erythromycin. Our patient responded well to TMP-SMX and showed signs of improvement after 2 weeks of follow-up.

Conclusion

Nocardia should be considered as an etiological agent for chronic sinusitis in immunocompromised as well as immunocompetent individuals. It demands a special attention from the microbiologist because of its slow growing nature and expertise needed to identify it.

References

1. Katz P, Fauci AS. *Nocardia* asteroid sinusitis: presentation as a trimethoprim-sulfamethoxazole responsive fever of unknown origin. *JAMA* 1977; 238:2397-98.
2. Roberts SA, Bartley J, Braatvedt G, Ellis-Pegler RB. *Nocardia* asteroids as a cause of sphenoidal sinusitis: case report. *Clin Infect Dis* 1995;21:1041-42.
3. Unzaga MJ, Croveto MA, Santamaria JM, et al. Maxillary sinusitis caused by *Nocardia nova*. *Clin Infect Dis* 1996; 23(1):184-85.
4. Saubolle MA, Sussland D. *Nocardiosis*: review of clinical and laboratory experience. *J Clin Microbiol* 2003, 41: 4497-501.
5. Leaker B A, Hellyar GH, Neild C, Rudge M, Manse LL, Thompson FD. *Nocardiosis* in renal transplant unit. *Transplant* 1989; 21:2103-04.
6. Brown-Elliott BA, Brown JM, Conville PS, Wallace RJ, Jr. Clinical and laboratory features of the *Nocardia* spp. based on current molecular taxonomy. *Clin Microbiol Rev* 2006; 19: 259-82.
7. Conville PS, Fischer SH, Cartwright CH, Witebsky FG. Identification of *Nocardia* species by restriction endonuclease analysis of an amplified portion of the 16S rRNA gene. *J Clin Microbiol* 2000, 38:158-64.